

Fallopian tubes and ultrasonography: the Sion experience

Gautam Nandkishore Allahbadia, M.D.*

Department of Obstetrics and Gynecology, Lokmanya Tilak Municipal Medical College and General Hospital, Sion, Bombay, India

Objective: To compare the accuracy of three new ultrasonographic methods of detecting tubal patency and pathology with established methods like hysterosalpingography (HSG) and laparoscopy.

Design: Sixty-seven cases were evaluated by performing the Sion test using endosonography to check for tubal patency. The Sion procedure includes filling up the pouch of Douglas with approximately 300 mL of sterile normal saline to elucidate not only the patency but visualize the motility, the fimbriae, and peritubal adhesions, if present. We have compared the accuracy of this procedure with HSG and laparoscopy in 24 infertile women. Color-coded duplex Doppler sonography was used in 38 patients to check for tubal patency.

Results: Our experience at the Sion Hospital using the three new ultrasonographic techniques for evaluating the status of the fallopian tubes is very encouraging. The accuracy with the three modes shows agreement in >90% of cases with established investigative modalities such as HSG and laparoscopy.

Conclusion: These three new investigative modalities are offered not as substitutes for HSG, laparoscopy, hysteroscopy, or salpingoscopy but as office-screening procedures that would be complementary to the armamentarium of infertility investigations already available.

Fertil Steril 1992;58:901-7

Key Words: Fallopian tubes, ultrasonography, infertility

The development of ultrasound (US) has provided the clinician with the opportunity to visualize the pelvic reproductive organs noninvasively. The use of US for the diagnosis and treatment of infertility has progressed rapidly to become an integral part of the management of the infertile woman. Examinations for each component of the reproductive tract have been refined. Thus, the diagnosis of uterine, tubal, and ovarian pathology has been facilitated by the use of ultrasonography. The normal fallopian tube is not usually seen by transvaginal sonography unless some fluid surrounds it. If enough pelvic fluid is present, the fallopian tube and even the fimbrial end may be detected. It is possible to enhance detection of the tubes by selecting a midcycle period for the scan because of the existence of increased pelvic fluid at that time (1). Determining if the fal-

lopian tubes are patent is part of the initial evaluation procedure in seeking the cause of infertility. The ability of transabdominal US to detect patency of at least one fallopian tube by demonstrating free fluid in the cul-de-sac was proved by more than one investigator (2, 3). The results were compared with conventional hysterosalpingograms, and US demonstrated bilateral occlusion with a sensitivity of 100% and showed tubal patency with a specificity of 96% (3). Compared with laparoscopy in the detection of at least unilateral tubal patency, as indicated by the accumulation of fluid in the cul-de-sac, ultrasonography agreed in 51 of 56 patients evaluated by Randolph et al. (4). Endosonography, as a tool for checking the patency of fallopian tubes, was an expected development in the giant strides taken in the field of gynecology. The Sion test (5) used transvaginal sonography to confirm tubal patency by visualizing turbulence near the fimbrial end when a mixture of air and saline was injected through a Foley catheter placed within the uterus. Deichert et al. (6) recommended the additional use

Received April 27, 1992; revised and accepted June 10, 1992.

* Reprint requests: Gautam N. Allahbadia, M.D., 262, My-Nest, Wadala, Bombay 400 031, India.

of pulsed wave Doppler in hysterosalpingo-contrast sonography as a supplement to gray scale imaging in cases of suspected tubal occlusion and in the event of intratubal flow demonstrable over a short distance.

One question that was not answered by these studies was the status (mobility and milieu exterior) of the fallopian tubes. The Sion procedure (7) effectively solved all the unanswered questions about sonosalpingography and hysterosalpingo-contrast sonography by sonographic delineation of the tubes facilitated by instillation of normal saline in the cul-de-sac. Tubal patency was next studied at our hospital by means of a color-coded duplex sonography with local injection of sterile normal saline. The color signals generated by the air bubbles make it possible to demonstrate tubal patency on both sides.

MATERIALS AND METHODS

One hundred twenty-nine patients were chosen from the gynecological clinics of three different institutions in Bombay. The present study began in October 1990 and is ongoing. The data presented are analyses up to March 31, 1992.

This study includes 67 infertile women who underwent the Sion test, 24 patients who had the Sion procedure performed on them, and 38 patients in whom the tubal factor was investigated using transabdominal color-coded duplex sonography. In addition, all these patients had a diagnostic laparoscopy and an hysterosalpingogram performed on them.

A detailed history was taken, and the nature and duration of infertility were noted. After performing the other routine investigations for infertility, the patency of fallopian tubes was checked by performing the Sion test, the Sion procedure, or color-coded duplex sonography. The allocation of patients to different investigative modalities was based largely on financial considerations, with the Sion test or the Sion procedure costing approximately \$2 and color-coded sonography costing approximately \$23. The above tests were performed in the preovulatory phase of the menstrual cycle. Hysterosalpingography (HSG) was carried out the next day using meglumine iohalamate 60% (Conray 280; Rhone Poulenc, Bombay, India), a water soluble dye. Diagnostic laparoscopy was performed in the secretory phase soon after the HSG under general anesthesia. A comparison of the accuracy of these newer techniques with HSG and laparoscopy was then done after analyzing the collected data.

The Sion Test

Transvaginal sonography is used to evaluate tubal patency (5) by means of a 5.0-MHz vaginal transducer. We are using the ATL Ultramark 4 machine (Advanced Technology Laboratories, Bothell, WA) that has real-time/2-D sector and linear imaging modes along with M mode and duplex Doppler capability with documentation by multifram camera and videocassette recorder. An 8 F Foley catheter is inserted into the uterine cavity, and 3 mL of saline is then injected into the Foley bulb, thus stabilizing the catheter within the uterine cavity. Scanning is now begun, and images of the uterus with the Foley catheter in situ are obtained in the sagittal (Fig. 1) and coronal plane. After scanning the uterus, left ovary, and right ovary, we go back toward the left ovary and concentrate on an area between the left cornu of the uterus and the left ovary. Approximately 20 mL of saline along with air are pushed through the Foley catheter. The flow of the saline and micrometer-sized air bubbles is observed on transverse section mode and the left tube if patent distends and the mixture of saline and air microbubbles flows out into the peritoneal cavity with considerable turbulence recorded on gray scale ultrasonography. We are in agreement with other investigators (8) that in transvaginal sonosalpingography observation of either forward flow of the saline and microbubbles for at least 5 seconds between pars intramuralis and isthmus tubae without interruption and hydrosalpinx formation and/or fimbrial turbulence to cul-de-sac are considered as the presence of tubal patency.

The good tolerance of intravenous injections of soluble galactose microparticles and micrometer-sized air bubbles has been demonstrated in echo-

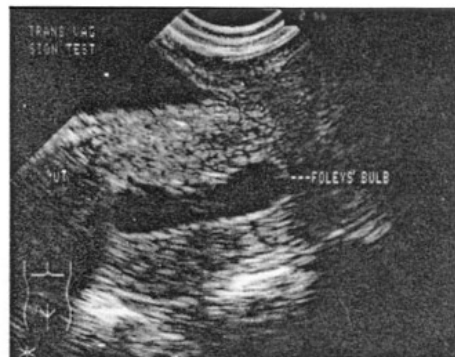


Figure 1 The Sion test. Uterus in a sagittal plane with the Foley bulb within the uterine cavity.

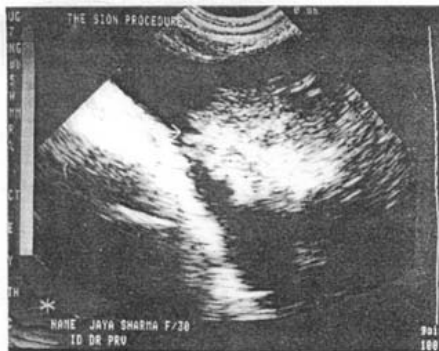

Figure 2 The Sion procedure. Arrow points to the free floating fimbrial end of the fallopian tube.

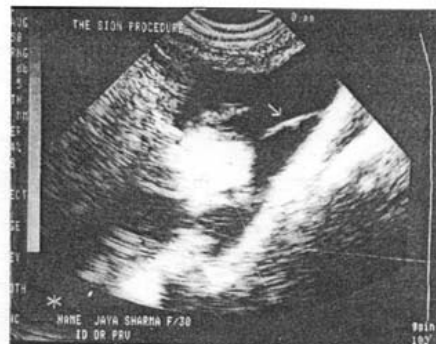

Figure 3 The Sion procedure. Arrow points to a filmy adhesion in the periadnexal region.

cardiographic studies involving >2,000 patients (6), and hence any concern for potential air embolization is really unjustified. The right tube is also checked for patency using the same technique. In the presence of bilaterally obstructed tubes, the uterine cavity was seen to expand without subsequent decompression, and reflux of saline and air microbubbles was seen very clearly in the stem of the Foley catheter. Almost all the patients with a bilateral obstruction complained of an acute groin pain that subsided on releasing injection pressure on the syringe. All the patients were allowed to rest for a short period of time and were then sent home on a 7-day course of ampicillin (Campicillin; Cadilla Laboratories Ltd., Ahmedabad, Gujrat, India) and metronidazole (Flagyl; Rhone Poulenc, Bombay, India).

The Sion Procedure

The Sion procedure (7) takes approximately 15 minutes as compared with the 5 to 6 minutes for the Sion test (5). Here the patient is not only given atropine sulfate (0.6 mg intramuscularly; Professor Gajjar's Standard Chemical Works Ltd., Bombay, India) but also tablet diazepam (5 mg of Valium 5; Roche Products Ltd., Bombay, India) orally half an hour before the procedure. After accomplishing what we have designated to be the Sion test, we continue to inject sterile normal saline until approximately 300 mL have flooded the pelvis. Now, with the adnexa and the uterus submerged in a fluid medium, we start a thorough rescanning of the pelvis again. If there is a bilateral tubal block and reflux of saline is seen in the stem of the Foley catheter, we proceed to fill up the pelvis by alternative means. In one case of secondary infertility in which the right tube was

blocked and there was partial spill from the left side, we used an 18-gauge needle inserted per abdomen through the suprapubic region after a thorough local infiltration using 2% xylocaine to inject 350 mL of sterile normal saline into the pelvis with all aseptic precautions. When surrounded by fluid, the normal tube appears as a 1-cm tubular echogenic structure that usually comes from the lateral aspect of the uterine cornu posterolaterally into the adnexal regions and cul-de-sac (9). The saline fills up the pelvis and delineates all sorts of adhesions; filmy and dense and even multiple thick septa in the periadnexal regions are depicted clearly (Figs. 2 to 4). All the patients undergoing this procedure are similarly given prophylactic antibiotics.

Color-Coded Duplex Sonography

We are using the Vingmed Sound CFM-750 ultrasonography machine (Vingmed, Salt Lake City, UT) providing color M mode with 128 color flow

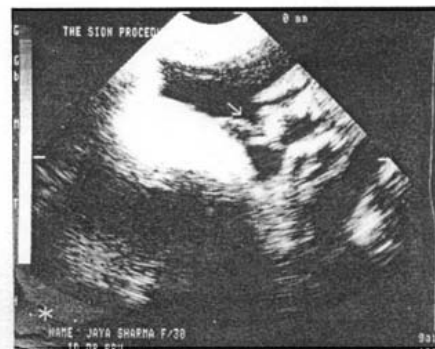

Figure 4 The Sion procedure. Arrow points to multiple thick septa in the periadnexal region.

Table 1 Accuracy of the Three New Techniques as Compared With HSG and Laparoscopy

| Method | Bilateral patency | Bilateral block | Left-sided block | Right-sided block |
|--|-------------------|-----------------|------------------|-------------------|
| The Sion test (n = 67) | 53 | 8 | 4 | 2 |
| HSG (n = 67) | 49 | 12 | 4 | 2 |
| Laparoscopy (n = 67) | 55 | 6 | 4 | 2 |
| The Sion procedure (n = 24) | 21 | — | 1 | 2 |
| HSG (n = 24) | 22 | — | 1 | 1 |
| Laparoscopy (n = 24) | 22 | 1 | 1 | — |
| Color-coded duplex sonography (n = 38) | 32 | 4 | 2 | — |
| HSG (n = 38) | 33 | 3 | 1 | 1 |
| Laparoscopy (n = 38) | 34 | 3 | 1 | — |

maps. The 3.5-MHz abdominal transducer is used for our procedure. The spatial peak temporal average intensity was approximately 80 mW/cm², whereas pulse repetition frequencies of this apparatus were 2 to 32 kHz. The flow directed to the transducer is displayed in red; the flow directed away from the transducer is in blue. The velocity of flow is coded by brightness, the brighter blue or red hues representing faster velocities. Frequency dispersion, which is determined as the variance of the signal by the autocorrelator, is added to the velocity signal as an alternate hue such as green, which makes any turbulent flow appear not as a pure red or blue but as a distinctive speckled yellow or cyan (mosaic appearance).

After a pelvic examination, the patient is brought to the edge of the table and the vagina is disinfected with an antiseptic solution. A speculum examination is then performed and a Leech-Wilkinson cannula is screwed on to the cervical canal. A routine pelvic sonographic examination is then performed. The uterus is used as a landmark for depiction of other adnexal structures. Once the color signals are on, an anatomic Doppler window can be selected to get a selective spectral waveform from a chosen vessel. The Doppler window is now narrowed down to an area between the left ovary and the uterus. Approximately 20 mL of sterile normal saline is now injected through the cannula. Direction and flow into and out of the fallopian tubes were observed with color-coded sonography. For diagnosing patency of fallopian tube with abdominal color flow imaging, there should be a recording of color flow signals during perturbation of normal saline for at least 10 seconds. When no fluid was seen to enter the peritoneal cavity, tubal occlusion was diagnosed. The same procedure is repeated on the right side. Each tube can be assessed separately, and the free spill from each tube is depicted with a characteristic color bruit showing phasic indeterminate color assignment. The

patients are allowed to rest for some time and when comfortable are sent home on a 7-day course of prophylactic antibiotics.

RESULTS

The results of the accuracy of the three new techniques as compared with HSG and laparoscopy can be divided into three sections (Table 1). When the results of the Sion test were compared with HSG and laparoscopy, there was 91.1% agreement, that is, patency or occlusion of the fallopian tubes. There was no febrile morbidity, and all patients complained of transient mild suprapubic pain at the time of injection of saline. Section B in Table 1 shows that there was 87.5% agreement regarding bilateral tubal patency. Regarding tubal block, there was agreement in 8.1% cases; therefore, on the whole there was an agreement in 95.6% cases.

Section C in Table 1 outlines the results of color-coded sonography as compared with HSG and laparoscopy. One case showing a left-sided tubal occlusion with color flow mapping showed bilateral patency subsequently with both HSG and chromopertubation. In this group, there was 92% overall agreement between the three investigative modalities. Laparoscopy confirmed all findings with the other two techniques and, in addition, picked up peritubal adhesions in two cases and endometriosis in one case showing free spill with all three methods.

DISCUSSION

Before the accurate anatomical description of the human fallopian tubes by Gabrielle Fallopio in 1561, the concepts about the tubes were imaginary, vague, and erratic. Once the anatomy was understood, physiology was bound to attract attention. Patency of the tubes was the earliest and, until recent decades, the only aspect of tubal function that was

studied and evaluated. The beginning of this century was marked by the development of diagnostic procedures for tubal patency and pathology with the introduction of HSG, tubal pertubation, and laparoscopy. Radiologic studies complement endoscopic investigations as each provides information, albeit with a varying degree of accuracy, about one or more segments of the oviduct, and each can also be used to confirm the findings of the other.

Today, transvaginal transducers have a major role in the management and treatment of patients with gynecological infertility. Specifically, transvaginal sonography is important in the precise monitoring of follicular development, guided follicular or cyst aspiration, and guided transcervical cannulation of the fallopian tube. Other applications of transvaginal sonography include evaluation of the adequacy of endometrial development and depiction of normal and abnormal physiological changes in the ovary and uterus. Inflammatory processes of the tube, such as hydrosalpinx, pyosalpinx, or tubo-ovarian abscesses, demonstrate typical sonographic patterns on transvaginal sonography. The addition of pulsed Doppler capabilities to transvaginal probes may also afford methods to assess uterine and ovarian perfusion changes. Transvaginal sonosalpingography using normal saline (5), with its accuracy and safety, is a promising screening and diagnostic technique in the evaluation of tubal patency on an ambulatory basis. According to Tüfekci et al. (8), the results obtained from transvaginal sonosalpingography and laparoscopy were completely consistent for 76.32% of cases and partially consistent for 21.05% of cases. Recently, there have been many studies published using transvaginal hysterosalpingo-contrast sonography for tubal diagnosis that also reiterate the fact that sonographic diagnosis of patent tubes is reliable (6, 10, 11). Overall, complete agreement between the sonographic finding and that of conventional methods such as HSG and laparoscopic chromopertubation has so far been found in 65% to 71% of cases (6). As stated by other researchers (3, 4, 6), HSG presents a number of potential problems in evaluating the upper genital tract, including exposure to ionizing radiation. The amount of radiation to the ovaries during HSG is classified to be in the "high gonad dose" group (12). Iodinated contrast materials could produce an anaphylactic reaction in a sensitized patient. The information is limited to internal müllerian duct anatomy. Moreover, this technique requires radiologic facilities and associated staff.

Ultrasonography offers certain advantages over HSG. The elimination of iodinated contrast and

ionizing radiation removes their associated risks. Ultrasonography provides a three-dimensional view of the entire pelvis, thus delineating uterine abnormalities at the time of the study. It may be performed by a gynecologist with standard real-time equipment, an increasingly common commodity in modern infertility practice. Thus it may provide a safer and more convenient screen of pelvic anatomy early in an evaluation if the equipment and expertise are readily available.

One of our patients (01), a case of secondary infertility, showed no spill bilaterally with laparoscopic chromopertubation, and further, the pelvis was seen to be filled with dense as well as filmy adhesions. The Sion procedure confirmed the multiplicity of adhesions and further demonstrated poor mobility of tubes with a left-sided partial spill. Hysterosalpingography showed bilateral terminal hydrosalpinx with bilateral localized spill, suggestive of peritubal adhesions.

Patient 02, a 25-year-old patient with primary infertility, had an HSG showing a left-sided midsegment block with right-sided free spill. On laparoscopy, the additional findings were a thickened right tube with dense left-sided peritubal adhesions. The Sion procedure not only confirmed the findings of laparoscopy but also showed that the left ovary not visualized separately on laparoscopy was normal with no obvious pathology.

Patient 03, a case of secondary infertility, had undergone an exploration with adhesiolysis 10 years previously. At the time of exploration, bilateral patent tubes were demonstrated. An HSG done recently demonstrated bilateral free spill but with evidence of terminal dilatation. On laparoscopy, there were filmy adhesions seen, and a right terminal hydrosalpinx was noted along with bilateral free spill. In this particular case, the Sion procedure showed no spill on the right side. Filmy adhesions were picked up as were also thickened septa and loculated fluid-filled areas in the region of the right adnexa. On the left side, even the fimbrial motion showing free spill was picked up clearly. These three cases highlight the usefulness of the Sion procedure in evaluating infertility because of tubal disease. They also confirm the importance of transvaginal sonography in the diagnosis of infertility.

The advent of duplex Doppler techniques in the late 1970s opened up a new field of sonographic investigation, namely, the direct recording of peripheral, abdominal, and cardiac blood flow, albeit limited to a relatively small sample volume. Normal and abnormal blood flow characteristics were defined

by duplex Doppler techniques, setting the stage for clinical acceptance of a new generation of sonographic imaging devices, namely, color Doppler units capable of displaying regional physiological and pathophysiological arterial and venous flow in the familiar anatomic format of a gray scale sonographic image (13). Color-coded sonography can be used in an office setting, which makes it more convenient for both the patient and physician. Difficulty in making a diagnosis of tubal occlusion arises in patients with dilated hydrosalpinges because flow through the dilated fallopian tube may simulate spillage on the Doppler ultrasonography screen (14). The limitation of this modality compared with conventional standard studies (HSG, laparoscopy) seems to be the impaired diagnostic value if no tubal flow can be demonstrated (10). In addition, tubal architecture is not demonstrated with color-coded sonography as it is with HSG. However, a recent study has shown this information is not useful in preoperative salpingoplasty procedures (15).

Today, we are on the threshold of an ultrasonographic revolution in the field of infertility. Ultrasonography is not only being used in tubal diagnosis (5, 7) but very much so in the treatment of tubal disorders. Fluoroscopic transvaginal fallopian tube catheterization in patients with proximal tubal obstruction is a proven successful treatment for infertility (16). Jansen et al. (17) developed an ultrasonographic guided technique for directing a catheter through the cervix and uterine cavity into the fallopian tube. This was followed by other workers using ultrasonographic guidance for selective tubal catheterization as well as tuboplasty procedures (18).

With the Sion test, the Sion procedure, and color-coded duplex sonography, we are as yet mastering the nuances of diagnostic fallopian tube US. The Sion test or sonosalpingography is offered as an inexpensive, noninvasive, simple screening test that can be done in the gynecologist's office at the same time as a pelvic examination. If the waterfall sign (5) (turbulence created by microbubbles injected under pressure) is not seen on one or both sides, the Sion procedure should be performed. Interfimbrial adhesions, which are easily overlooked during routine laparoscopy but easily found when catheterization of the tubal ostia is performed, can be a contributing factor to infertility (19). The Sion procedure would go a long way in identifying these filmy interfimbrial adhesions as also peritubal adhesions and loculated fluid collections in the adnexa or cul-de-sac. En bloc motion, "the sliding sign" of the organ(s) under study when simultaneous

pressure is applied to the pelvic organs transabdominally with the examiner's free hand and the endovaginal probe, strongly suggests the existence of pelvic adhesions and the tethering of the organ (e.g., ovary, tube) to the surrounding structures (1). Color-coded duplex sonography is a new diagnostic procedure that demonstrates normal findings and tubal patency with high reliability. The recent incorporation of color Doppler processing in transvaginal transducer/probes extends the scope of sonographic imaging from an anatomic to a physiological basis. The ability to assess utero-ovarian blood flow will have several applications in the assessment of women enrolled in assisted conception programs. Specifically, changes in ovarian and uterine perfusion during spontaneous or induced folliculogenesis can be assessed and thereby optimized so that embryo replacement is performed when most conducive to implantation (20, 21). Other possible applications of transvaginal color Doppler sonography include definitive diagnosis of ovarian torsion, assessment of perfusion to either normotopic or ectopic early (5 to 9 weeks) pregnancies by their choriodecidual flow, and detection and differentiation of sonographically complex benign ovarian masses from malignant ones (22). Tiny ovarian cysts, small intramural and subserous fibroids, and any other pelvic pathologies are easily picked up on endosonography, but with the color signals on we can go much further and pick up even arteriovenous malformations (23). Color flow Doppler studies of the uterine and ovarian vessels in infertile subjects raise the interesting question whether blood flow changes play a role in infertility (24, 25). Thus, along with a patency test, color-coded sonography could stretch the investigative spectrum of an infertile woman toward vascular causes.

Acknowledgments. The author gratefully acknowledges the guidance given by Nandkishore Allahbadia, F.R.C.O.G., Senior Consultant, Rotunda Nursing Home, Bombay, and Pratibha Vaidya, M.D., Head of Department of Obstetrics and Gynaecology, Lokmanya Tilak Municipal Medical College and General Hospital, Bombay. I also thank Snehlata Deshmukh, M.S., Dean, Lokmanya Tilak Municipal Medical College and General Hospital, Bombay, for giving me permission to conduct this study.

REFERENCES

1. Timor Tritsch IE, Rottem S. Transvaginal ultrasonographic study of the fallopian tube. *Obstet Gynecol* 1987;70:424-6.
2. Sharma RP. Fallopian tube patency by ultrasound scan. *J Obstet Gynaecol India* 1989;39:700-1.
3. Richman TS, Viscomi GN, DeCherney A, Polan ML, Alcebo LO. Fallopian tubal patency assessed by ultrasound following fluid injection. *Radiology* 1984;152:507-10.

4. Randolph JR Jr, Ying YK, Maier DB, Schmidt CL, Riddick DH. Comparison of real-time ultrasonography, hysterosalpingography, and laparoscopy/hysteroscopy in the evaluation of uterine abnormalities and tubal patency. *Fertil Steril* 1986;46:828-32.
5. Allahbadia GN, Nalawade YV, Patkar VD, Niyogi GM, Shah PK. The Sion Test. *Aust NZ J Obstet Gynaecol* 1992;32(1): 67-70.
6. Deichert U, Schlieff R, van de Sandt M, Daume E. Transvaginal hysterosalpingo-contrast sonography for the assessment of tubal patency with gray scale imaging and additional use of pulsed wave Doppler. *Fertil Steril* 1992;57:62-7.
7. Allahbadia G, Nalawade Y, Panjwani M, Vaidya P, Merchant S. The Sion procedure—a preliminary report. *Bombay Hospital Journal*. In press.
8. Tüfekci EC, Girit S, Bayirli E, Durmuşoğlu F, Yaltı S. Evaluation of tubal patency by transvaginal sonosalpingography. *Fertil Steril* 1992;57:336-40.
9. Goldstein SR. Endovaginal ultrasonography. 1st ed. Salem (MA):Alan R. Liss, Inc., 1988.
10. Schlieff R, Deichert U. Hysterosalpingo-contrast-sonography of the uterus and fallopian tubes: results of a clinical trial of a new contrast medium in 120 patients. *Radiology* 1991;178: 213-5.
11. Fobbe F, Becker R, Koch HC, Hammerstein J, Wolf KJ. The demonstration of the patency of the uterine tubes with color coded duplex sonography in combination with ultrasonic contrast media. *ROFO* 1991;154(4):349-53.
12. Bokstedt H. Protection of the patient in x-ray diagnosis. Oxford:IRCP, Publication No. 16, 1969.
13. Foley WD, Erickson SJ. Color Doppler flow imaging. *AJR* 1991;156:3-13.
14. Peters AJ, Coulam CB. Hysterosalpingography with color Doppler ultrasonography. *Am J Obstet Gynecol* 1991;164: 1530-4.
15. Groff TR, Edelstein JA, Schlenken RS. Hysterosalpingography in the preoperative evaluation of tubal anastomosis candidates. *Fertil Steril* 1990;53:417-20.
16. Thurmond AS. Selective salpingography and fallopian tube recanalization. *AJR* 1991;156:33-8.
17. Jansen RP, Anderson JC, Sutherland PD. Nonoperative embryo transfer to the fallopian tube. *N Engl J Med* 1988;319: 288-91.
18. Lisse K, Sydow P. Fallopian tube catheterization and recanalization under ultrasonic observation: a simplified technique to evaluate tubal patency and open proximally obstructed tubes. *Fertil Steril* 1991;56:198-201.
19. Nordenskjöld F, Ahlgren M. Interfimbrial adhesions. Detection and treatment of an easily overlooked cause of infertility. *J Reprod Med* 1984;29(8):595-6.
20. Deutinger J, Rudelstorfer R, Bernaschek G. Vaginosonographic velocimetry of both main uterine arteries by visual vessel recognition and pulsed Doppler method during pregnancy. *Am J Obstet Gynecol* 1988;159:1072-6.
21. Baber RJ, McSweeney MB, Gill RW. Transvaginal pulsed Doppler ultrasound assessment of blood flow to the corpus luteum in IVF patients following embryo transfer. *Br J Obstet Gynaecol* 1988;95:1226-30.
22. Fleischer AC. Ultrasound imaging—2000 assessment of utero-ovarian blood flow with transvaginal color Doppler sonography; potential clinical applications in infertility. *Fertil Steril* 1991;55:684-91.
23. Iqbalbhashian UN, Mitchell DG, Middleton WD, Schwartz RA, Goldberg BB. Iatrogenic femoral arteriovenous fistula: diagnosis with color Doppler imaging. *Radiology* 1989;170:749-52.
24. Goswamy RK, Williams G, Steptoe PC. Decreased uterine perfusion—a cause of infertility. *Hum Reprod* 1988;3(8):955-9.
25. Kurjak A, Kupesia-Urek S, Schulman H, Zalud I. Transvaginal color flow Doppler in the assessment of ovarian and uterine blood flow in infertile women. *Fertil Steril* 1991;56:870-3.